



RESENTING CLINICAL SIGNS

History: Grade 2/6 left-sided murmur. Coughing. Cough easily induced on tracheal palpation.
Radiographs show tracheal collapse, normal heart size.

DATE

4/7/22

ECHOCARDIOGRAPHIC FINDINGS

2D, M-mode, and Doppler study.

PERFORMED BY:

Dr. Brian Barnes

INTERPRETED BY

Keith Blass, DVM,
MS, DACVIM
(Cardiology)

Left atrial size is normal. The mitral valve leaflets are mildly thickened, and a mild jet of eccentric mitral regurgitation is present. Left ventricular dimensions are normal. Left ventricular systolic function is hyperdynamic. The aorta and aortic valve are normal. Right atrial and right ventricular dimensions are normal. The tricuspid valve leaflets are mildly thickened, and a mild jet of tricuspid regurgitation is present. TR velocity does not suggest the presence of pulmonary hypertension. The pulmonary artery and pulmonic valve appear normal, though trace pulmonic insufficiency is present. No obvious shunting lesions are visualized. No pericardial effusion or cardiac masses are seen.

ECG during echo: Sinus arrhythmia

PATIENT

Rosco Chinn

SPECIES

Canine

LA - 25.1 mm
RA - 18.9 mm
LVIDd - 23.3 mm
LVIDs - 12.7 mm
FS - 47.8%
LVOT - 1.30 m/s
RVOT - 0.95 m/s
TR - 2.23 m/s

ASSESSMENT/RECOMMENDATIONS

BREED

Mixed

SEX

MN

AGE

11 y

WEIGHT

6.55 kg

HOSPITAL NAME

Westview VH

REFERRING VET

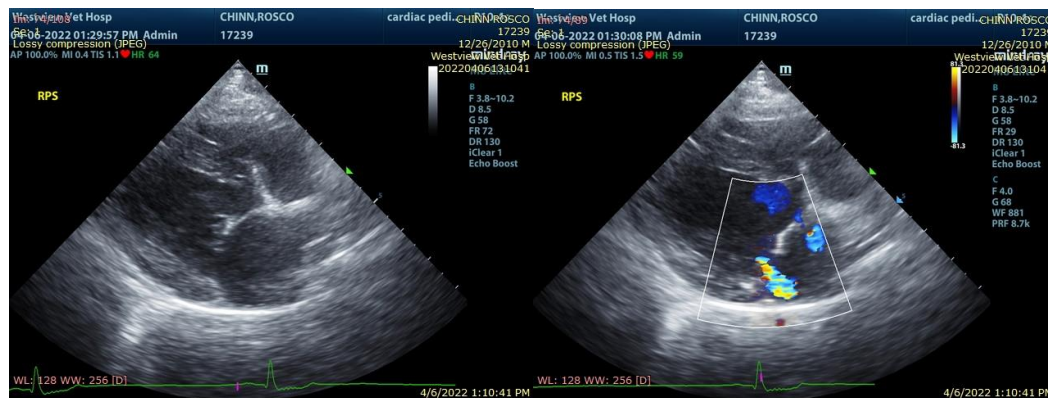
Dr. Barnes

Degenerative mitral and tricuspid valve disease

This examination demonstrates mild regurgitation of blood across Rosco's mitral and tricuspid valves resulting from degenerative valve disease. The hemodynamic effects of the regurgitations also appear to be mild, as Rosco does not have secondary dilation of any of his cardiac chambers. As such, Rosco's valvular diseases appear to be well-compensated, and it does not appear that there is a cardiac contribution to his cough.

No therapy is recommended at this stage of Rosco's valvular diseases.

A recheck echocardiogram is recommended in 6 months to monitor for disease progression.





DATE The information and recommendations provided are based on the images presented by the referring veterinarian. No evaluation can be communicated regarding pathology that was not visible in the image/video clips provided.
4/7/22

PERFORMED BY: Thank you for this referral. If the clinical or image interpretation does not parallel your findings or if I can be of any further assistance please contact me.

Dr. Brian Barnes

INTERPRETED BY Keith Blass, DVM, MS, DACVIM (Cardiology)
KeithBlass@gmail.com
631-804-5754

Keith Blass, DVM,
MS, DACVIM
(Cardiology)

PATIENT

Rosco Chinn

SPECIES

Canine

BREED

Mixed

SEX

MN

AGE

11 y

WEIGHT

6.55 kg

HOSPITAL NAME

Westview VH

REFERRING VET

Dr. Barnes